

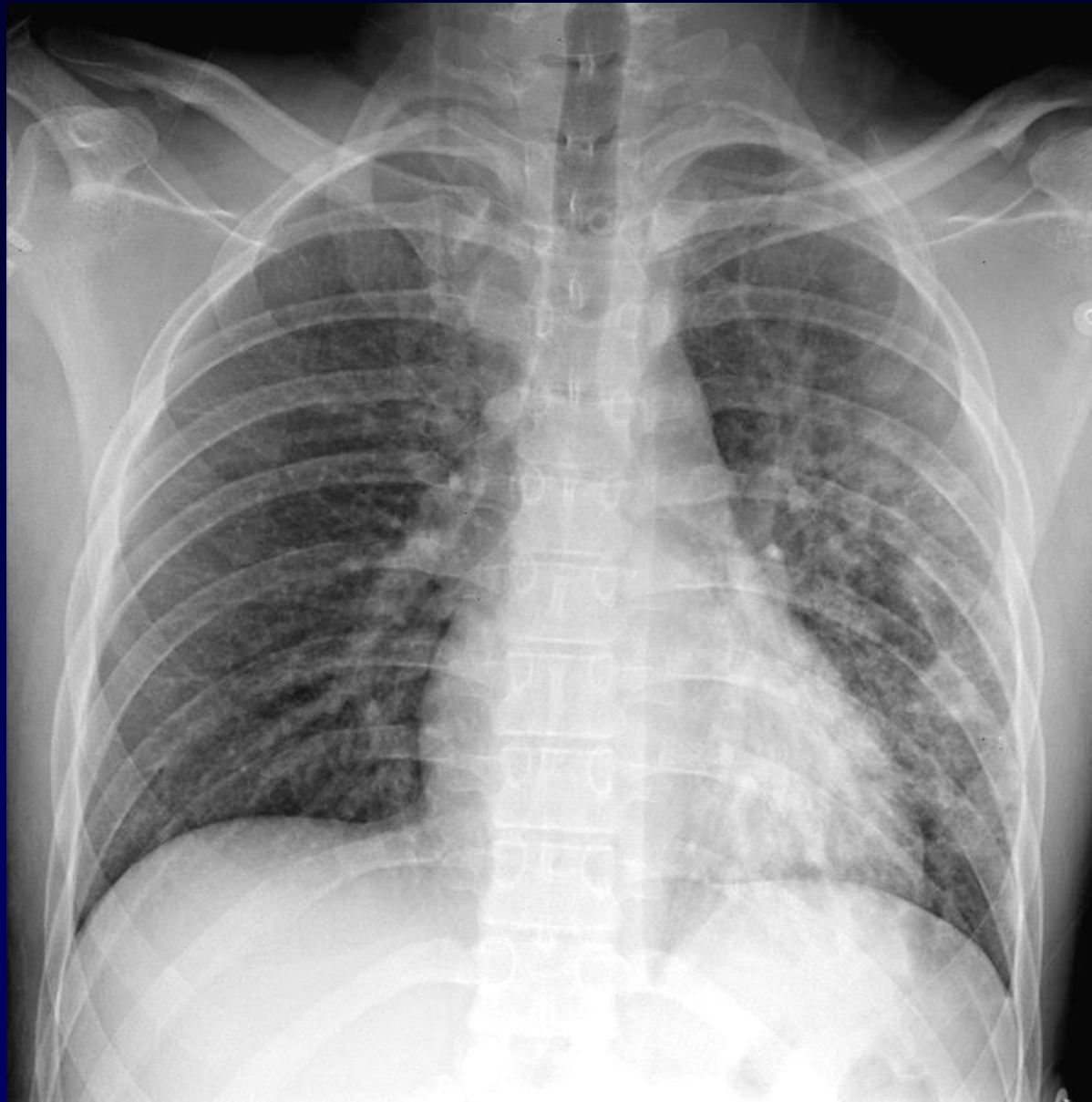

Alexis LACOUT

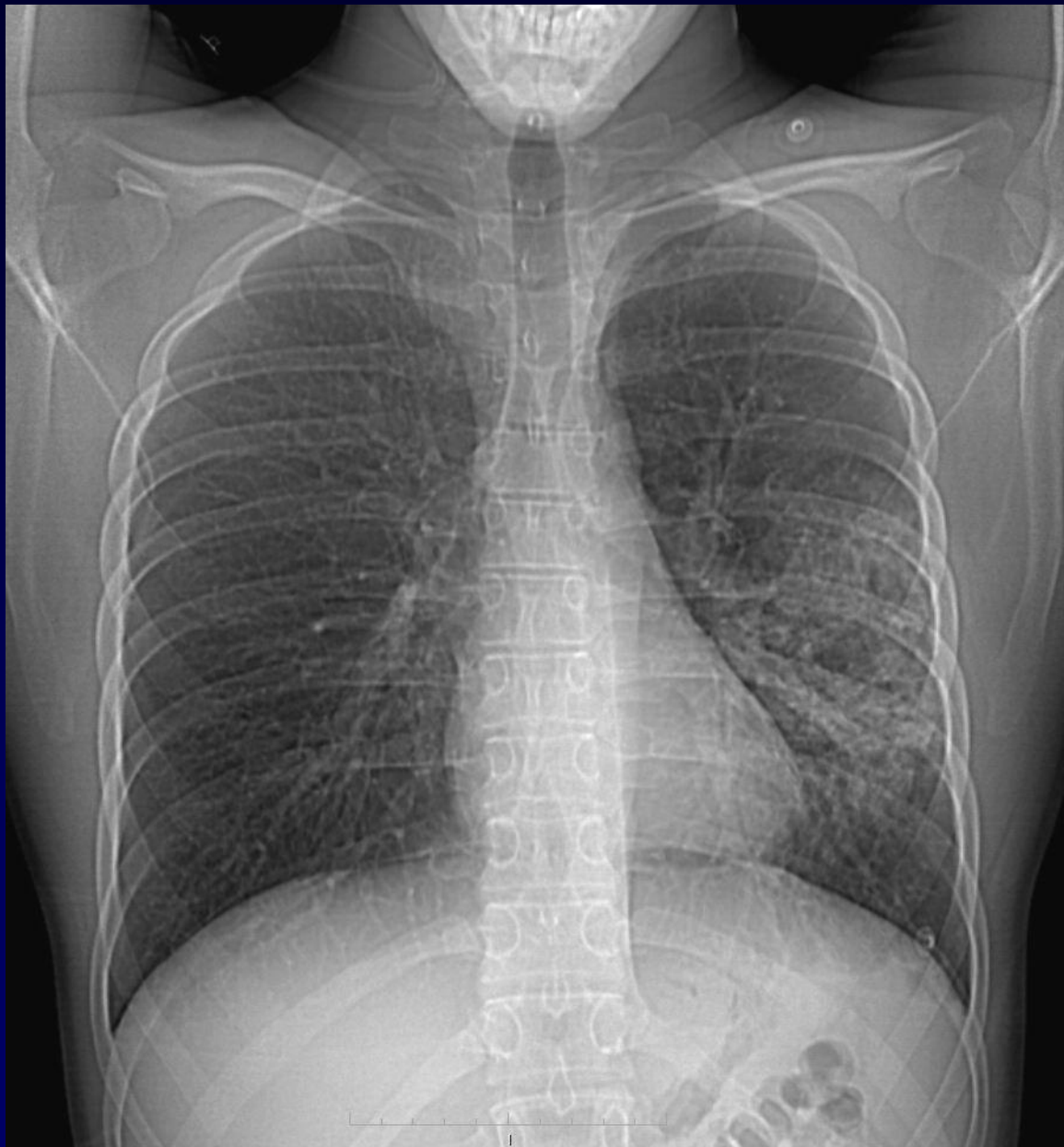Homme de 20 ans

Accident de moto

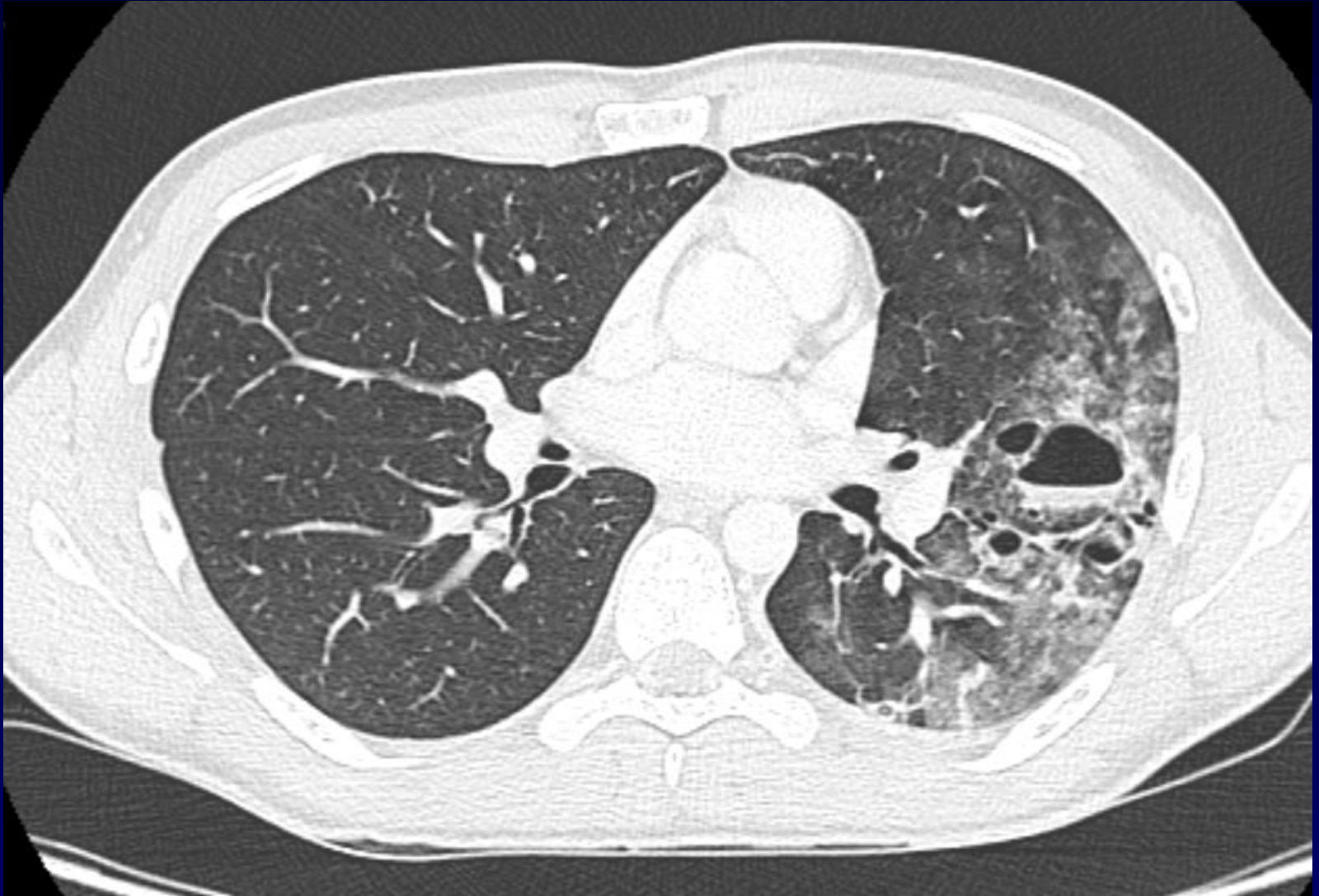
Chute à haute vitesse

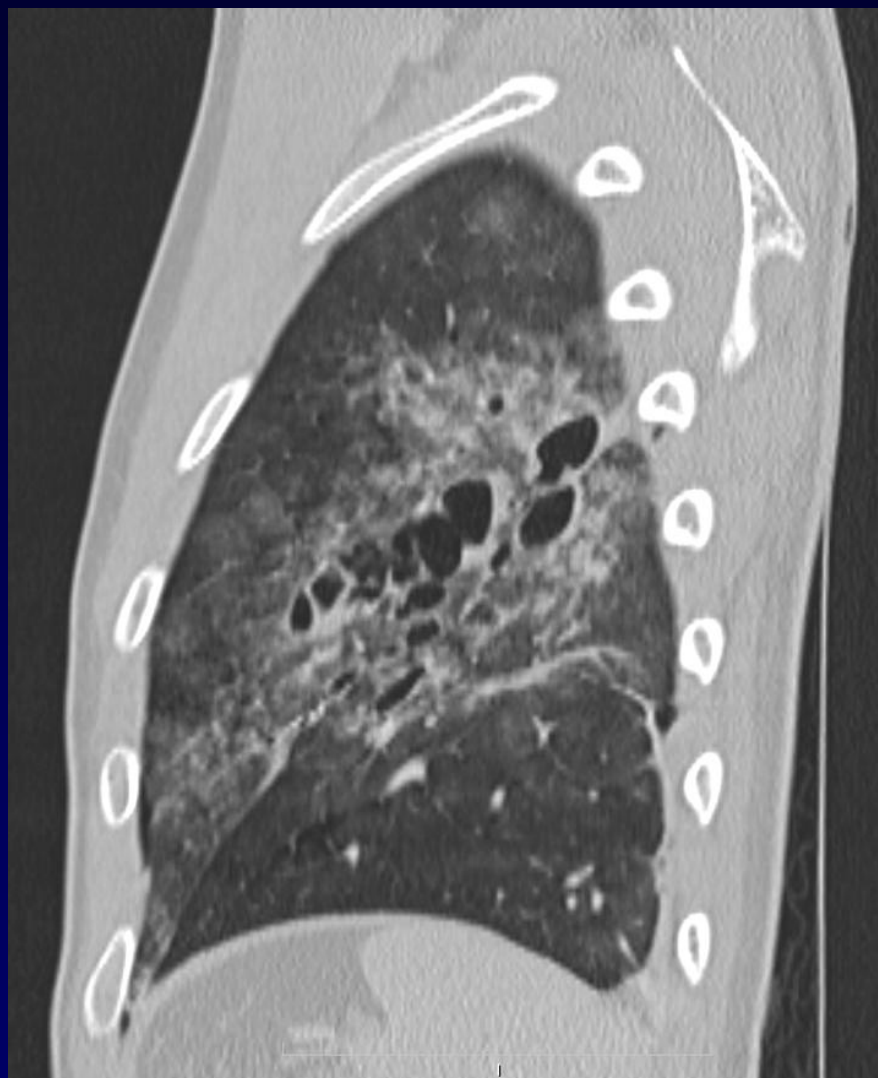
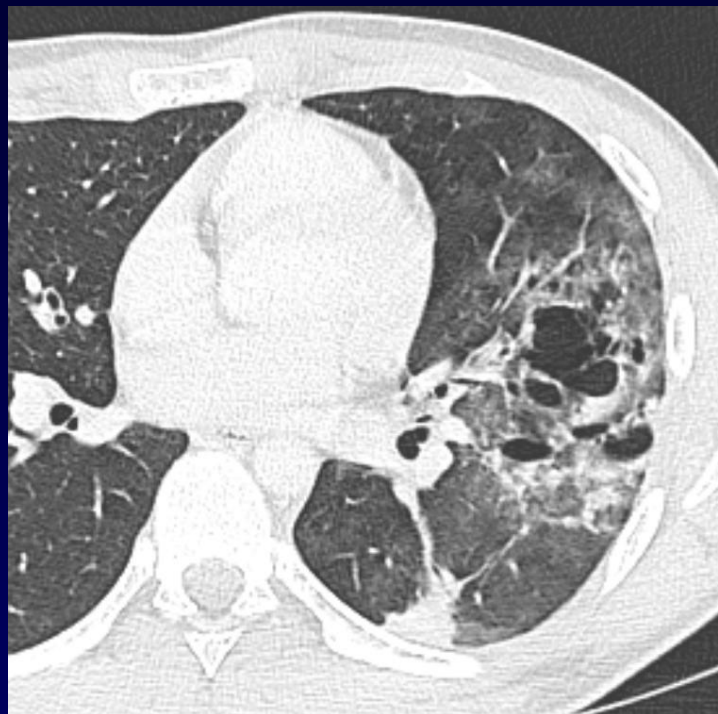
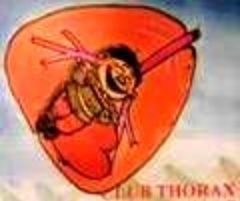

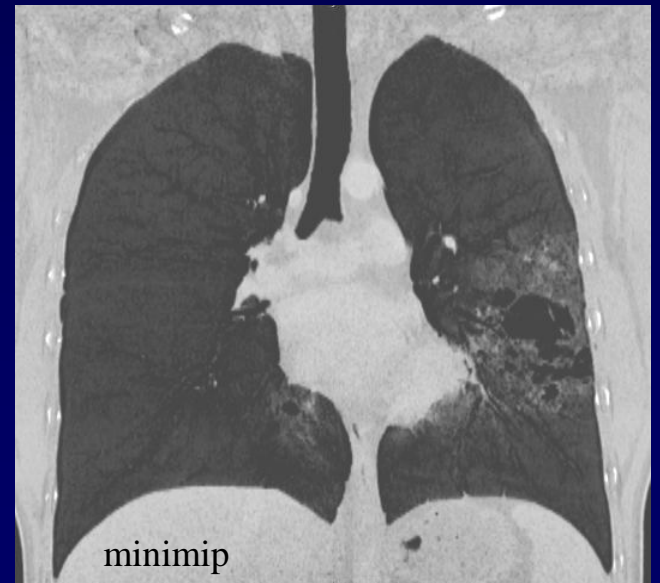
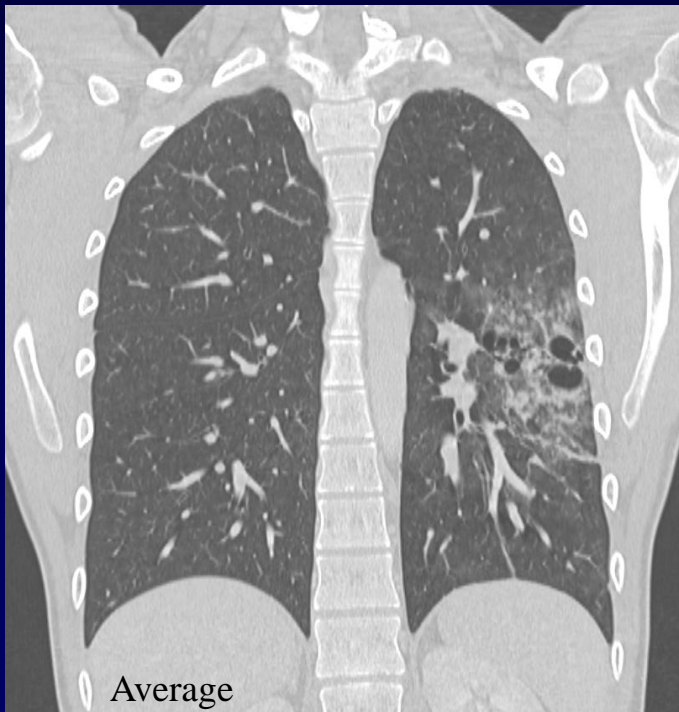
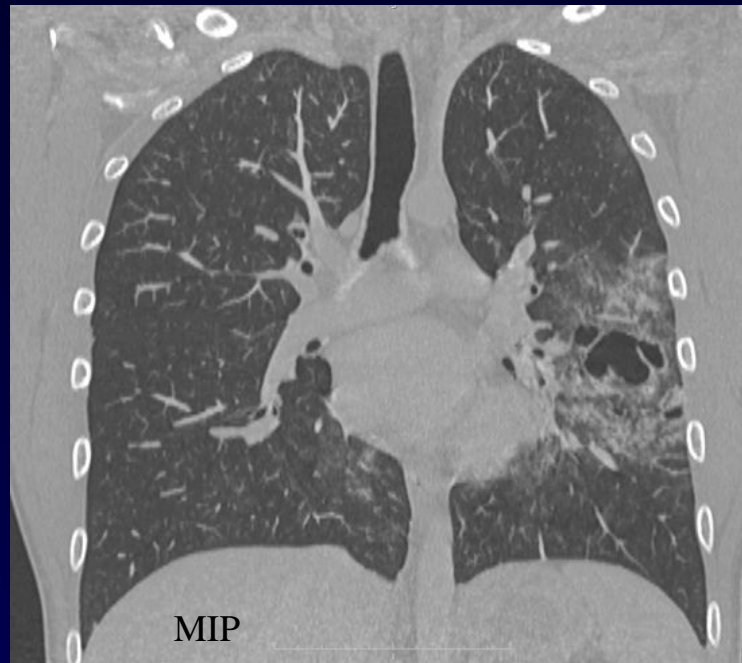
Thorax de face



Scout view

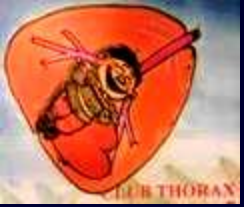







Diagnostic ?



Diagnostic

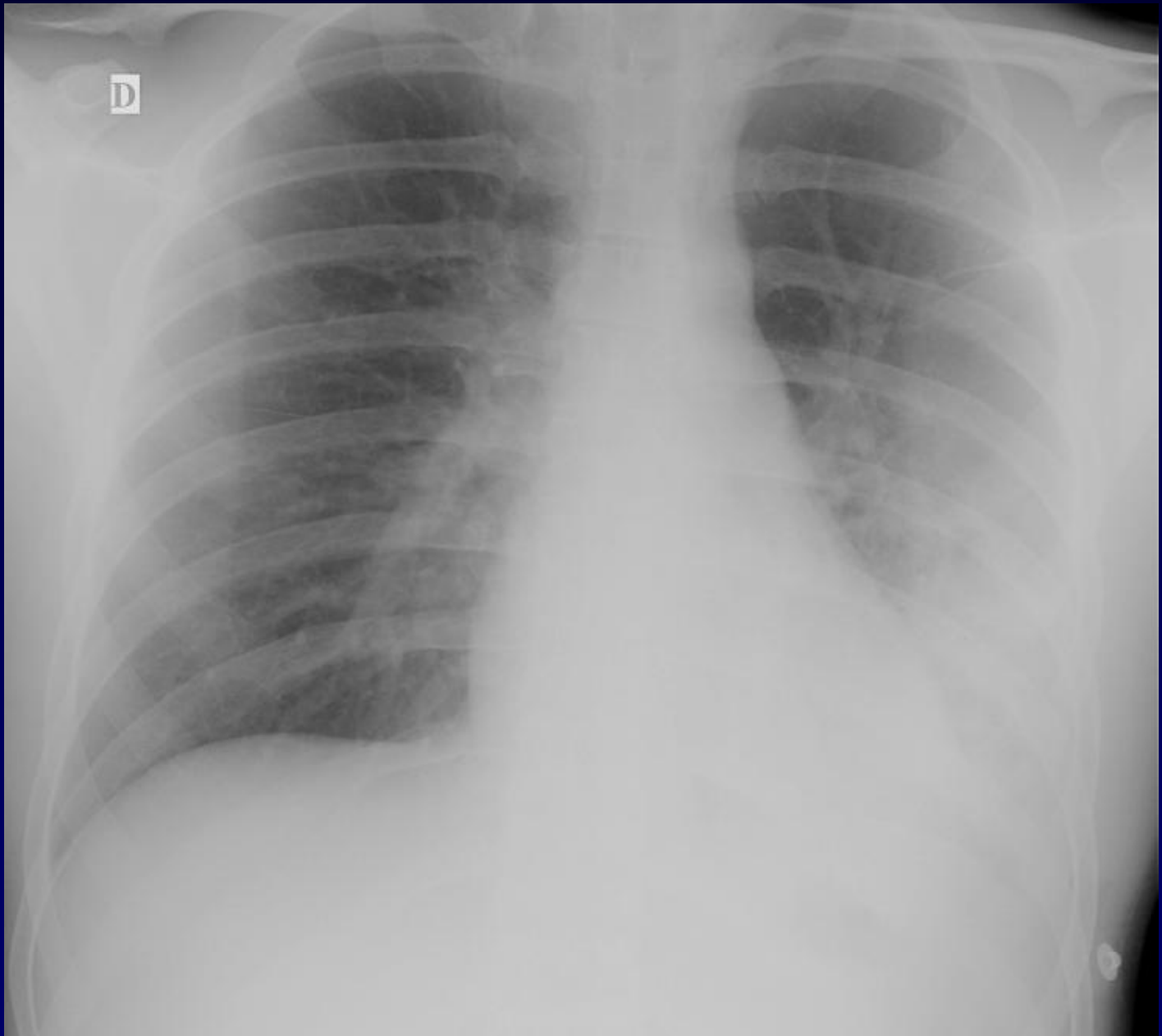
Contusion pulmonaire

Hémorragie alvéolaire

Pseudo-kystes pulmonaires ou pneumatocèles

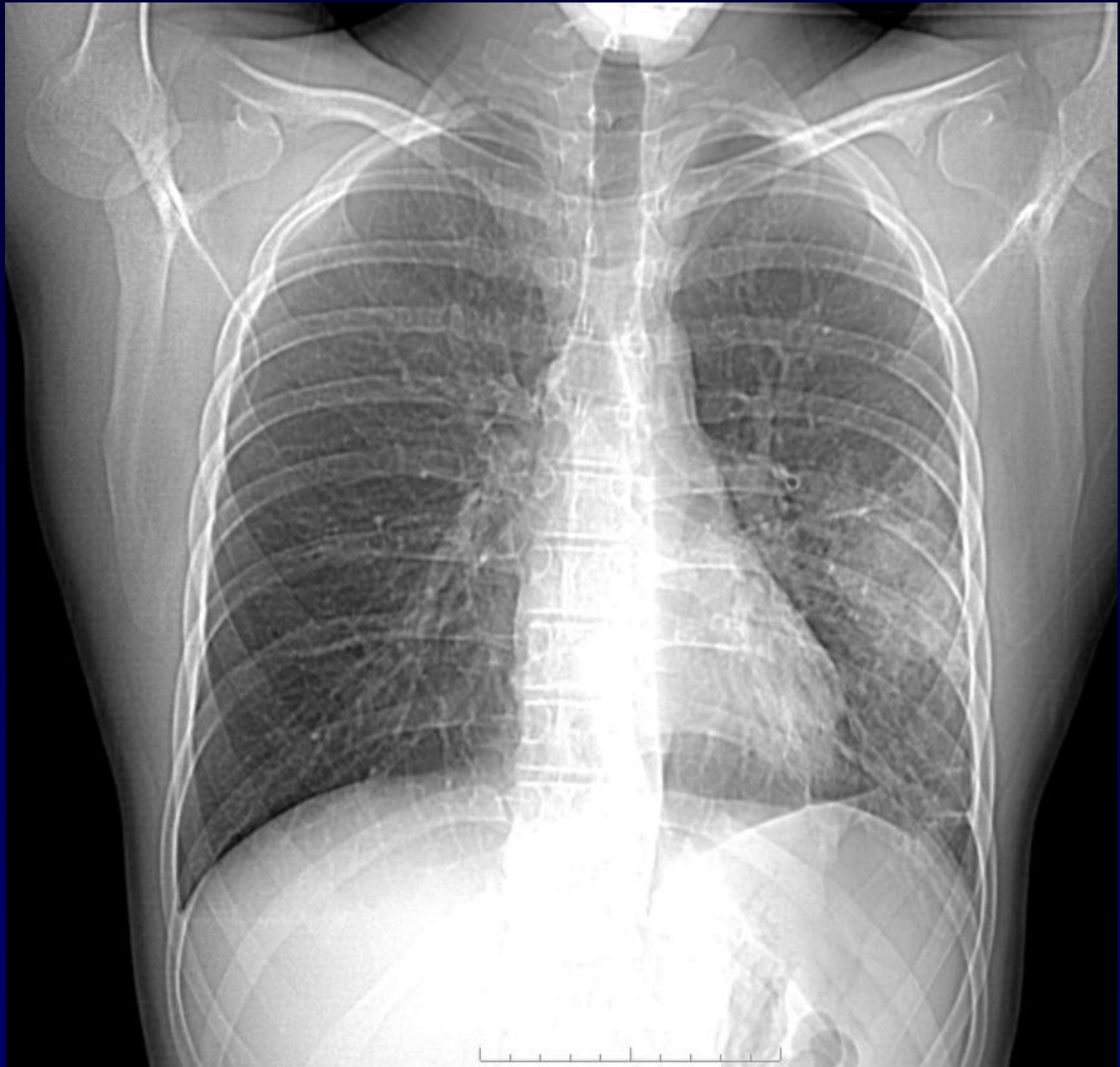

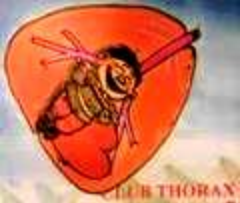J + 2



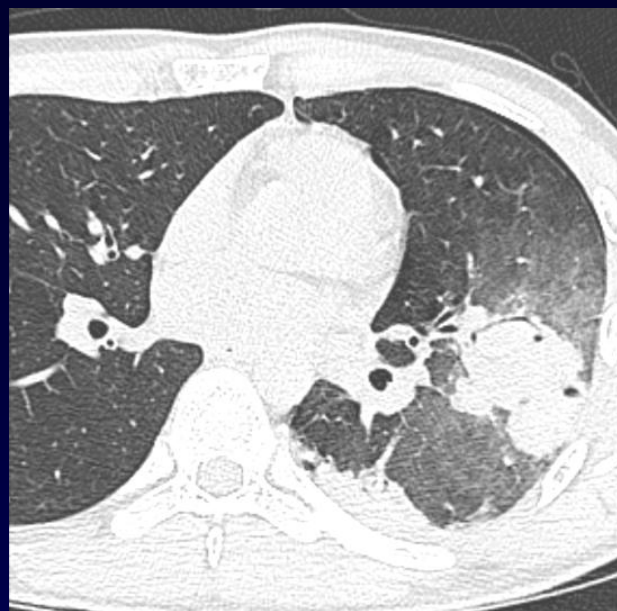
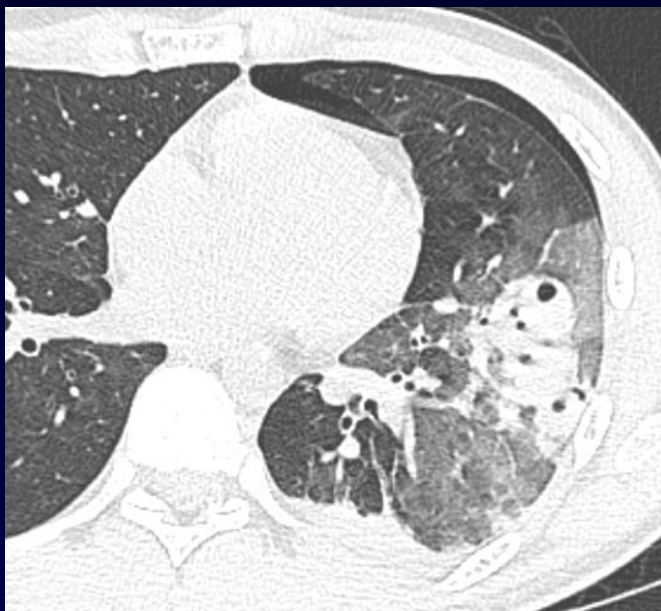
J + 4





J + 4



Petit pneumothorax associé

